

3D LASER SINTERING
ADDITIVE MANUFACTURING
CUSTOMIZED IMPLANTS SYSTEM

UNIQUELY

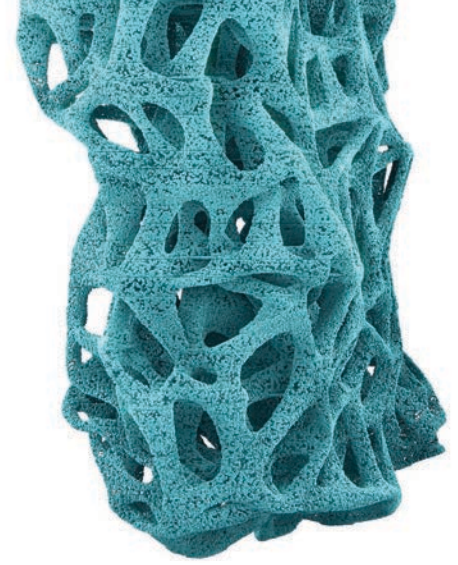
U



Superior Implant Technology

UNIQUELY U

3D LASER SINTERING/ADDITIVE MANUFACTURING CUSTOMIZED IMPLANTS SYSTEM



SUB-PERIOSTEAL IMPLANTS CAN BE ALSO INTEGRATED TO THE BONE AND FUNCTION AS ONE UNIT IN COMPARISON TO THE OLD DEVICE, SIMILAR TO CONVENTIONAL ENDOSTEAL IMPLANTS



Prof. Zvi Schwartz

A.B. Dental's new Customized Implants system exemplifies the pinnacle of technological initiative in our field, combining the latest 3D laser printing technology with ABGuidedService, A.B. Dental's exclusive patented computerized planning system that enables doctors to plan dental and facial restoration treatments with extraordinary precision.

TECHNOLOGICAL SOLUTION

The existing methods of manufacturing implants didn't allow for the control at the Nano level and the correct surface energy that we were looking for. We were determined to create something from scratch – to build an implant according to our precise design. And we weren't willing to compromise.

The Customized Implants system provides an effective, personalized restoration solution for especially complex clinical cases where conventional implants are not a suitable option. These high-end implants are individually designed and manufactured for patients who require mandibular and/or maxillofacial reconstruction due to severe disfigurement or massive bone loss caused by cancer, major bone trauma, or other medical conditions.

Our search brought us to 3D printing, a new manufacturing technique that had never before been used to build dental implants of this kind. For the first time, we could manufacture a form from titanium dust in a sequential layering process that allows for unprecedented precision.

SCIENTIFIC PUBLICATIONS

SCIENTIFIC REPORTS

Novel osteogenic Ti-6Al-4V device for restoration of dental function in patients with large bone deficiencies: design, development and implementation

D.J. Cohen, A. Cheng, A. Kahn, M. A viram, A. J. Whitehead, S. L. Hyzy, R. M. Clohessy, B. D. Boyan & Z. Schwartz

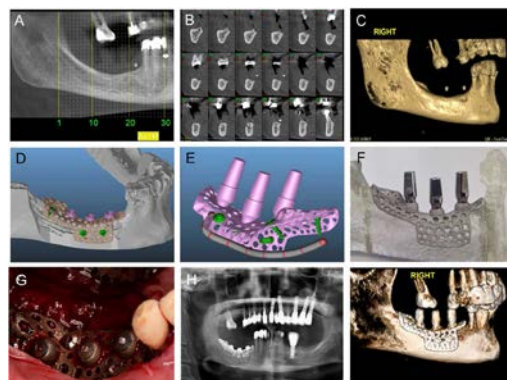
Published: Scientific Reports, 08 February 2016

Abstract

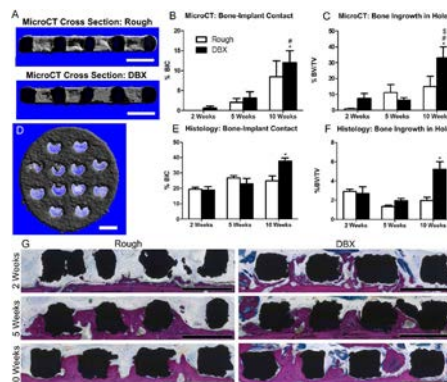
Custom devices supporting bone regeneration and implant placement are needed for edentulous patients with large mandibular deficiencies where endosteal implantation is not possible. We developed a novel subperiosteal titanium-aluminum-vanadium bone onlay device produced by additive manufacturing (AM) and post-fabrication osteogenic micro-/nano-scale surface texture modification.

Human osteoblasts produced osteogenic and angiogenic factors when grown on laser-sintered nano/micro-textured surfaces compared to smooth surfaces. Surface-processed constructs caused higher bone-to-implant

contact, vertical bone growth into disk pores (microCT and histomorphometry), and mechanical pull-out force at 5 and 10 w on rat calvaria compared to non-surface-modified constructs, even when pre-treating the bone to stimulate osteogenesis. Surface-modified wrap-implants placed around rabbit tibias osseointegrated by 6 w. Finally, patient-specific constructs designed to support dental implants produced via AM and surface-processing were implanted on edentulous mandibular bone. 3 and 8 month post-operative images showed new bone formation and osseointegration of the device and indicated stability of the dental implants.



Cellular response to laser sintered disks with smooth or rough surfaces



Cellular response to laser sintered disks with smooth or rough surfaces



Implant Surface Design Regulates Mesenchymal Stem Cell Differentiation and Maturation

B.D. Boyan, A. Cheng, R. Olivares-Navarrete and Z. Schwartz

Published: *Advances in Dental Research* 2016, Vol. 28(1) 10–17

Abstract

Changes in dental implant materials, structural design, and surface properties can all affect biological response. While bulk properties are important for mechanical stability of the implant, surface design ultimately contributes to osseointegration.

This article reviews the surface parameters of dental implant materials that contribute to improved cell response and osseointegration. We focus on how surface design affects mesenchymal cell response and differentiation into the osteoblast lineage.

Surface roughness has been largely studied at the microscale, but recent studies have highlighted the importance of hierarchical micron/submicron/Nano surface roughness, as well as surface roughness in combination with surface wettability.

Integrins are transmembrane receptors that recognize

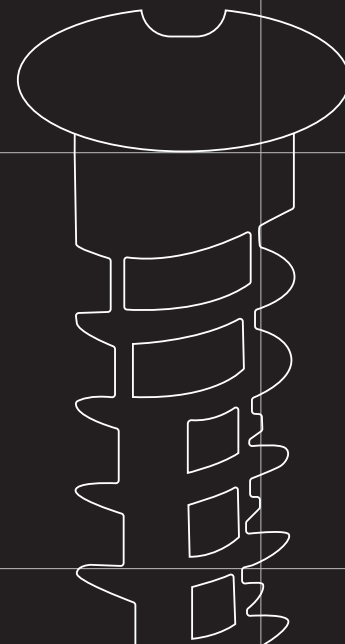
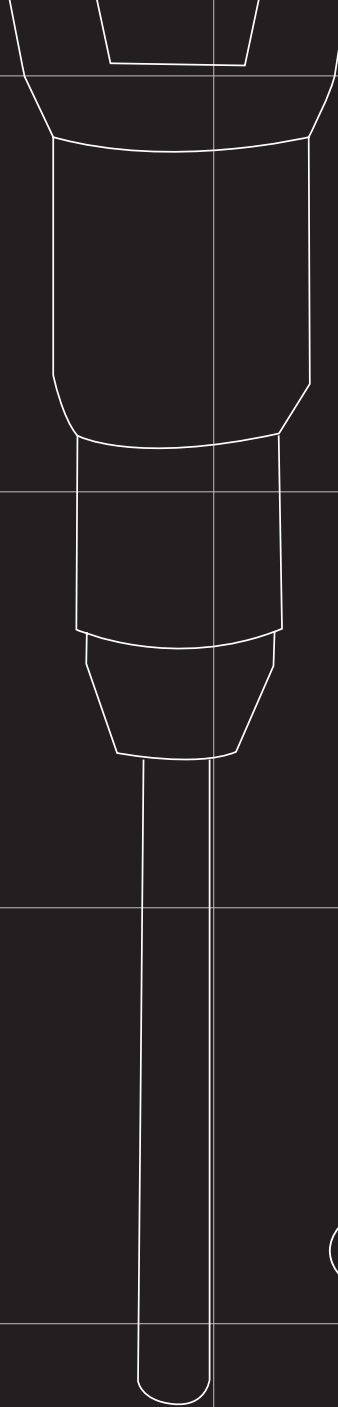
changes in the surface and mediate downstream signaling pathways. Specifically, the noncanonical Wnt5a pathway has been implicated in osteoblastic differentiation of cells on titanium implant surfaces.

However, much remains to be elucidated. Only recently have studies been conducted on the differences in biological response to implants based on sex, age, and clinical factors; these all point toward differences that advocate for patient-specific implant design.

Finally, challenges in implant surface characterization must be addressed to optimize and compare data across studies.

An understanding of both the science and the biology of the materials is crucial for developing novel dental implant materials and surface modifications for improved osseointegration.

COMPLEMENTARY PRODUCTS CATALOG





T10-FS
Handle
fixation screw



30 mm

T10-FS,30
Fixation Screw
Driver insert



T5-FS-3,20
Contra angle
driver for
fixation screw



T5-FS-3,25
Contra angle
driver for
fixation screw



TD 1.2
TD 1.5



TDG-1.5.19

FIXATION SCREWS



FS-2,7



FS-2,9



FS-2,11



FS-2,13



FS-2.3,7



FS-2.3,9



FS-2.3,11



FS-2.3,13

EXPOSURE PHASE



Ib-LPI
Cover screw for
customized implant



P0-LPI,3
Healing cap for
customized implant



P0-LPI,5
Healing cap for
customized implant

OVERDENTURE RESTORATION-P25



P25-LPI,1



P35-LPI,2



P25
Metal cover



P25-a,b/20
Locator Extended Range
Male processing package
(Yellowm - extra soft)



P25-a,b/20
Pink - soft



P25-a,b/20
Purple - strong



P25-a,b/20
Transparent - standard

SCREW RETAINED RESTORATION - P12



P12-LPI,T/L
Temporary Flat
Connection Abutment
for customized implant



P12a-LPI
Flat connection
abutment for customized
implant



P12-LP1
Flat connection
abutment for
customized implant



P12p
Flat connection Plastic
sleeve for customized
implant



D1-LPI
Analog for
customized implant



D2-P12-LPI,15
Impression Transfer for
Flat Connection Abutment
for customized implant



D2aL-LPI
Long fixing screw for
customized implant

SCREW RETAINED RESTORATION - P16



P16-LPI,1
Straight adaptor for customized implant



P16-LPI,2
Straight adaptor for customized implant



P16-LPI,3
Straight adaptor for customized implant



P14b
Plastic sleeve for angular adaptor



P14-bR
Cobalt chrome sleeve for angular adaptor



P14-bT
Titanium sleeve for angular adaptor



P0-P14,5
Healing cap for P14



P0-P14,7
Healing cap for P14



D1-P14
Analog for P14



D2-P14
Transfer for P14



P14,sc
Scanning base for angular adaptor



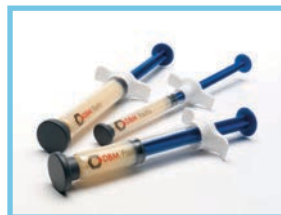P14-bRs
Cobalt chrome short sleeve



P14,bTs
Scanning base for angular adaptor



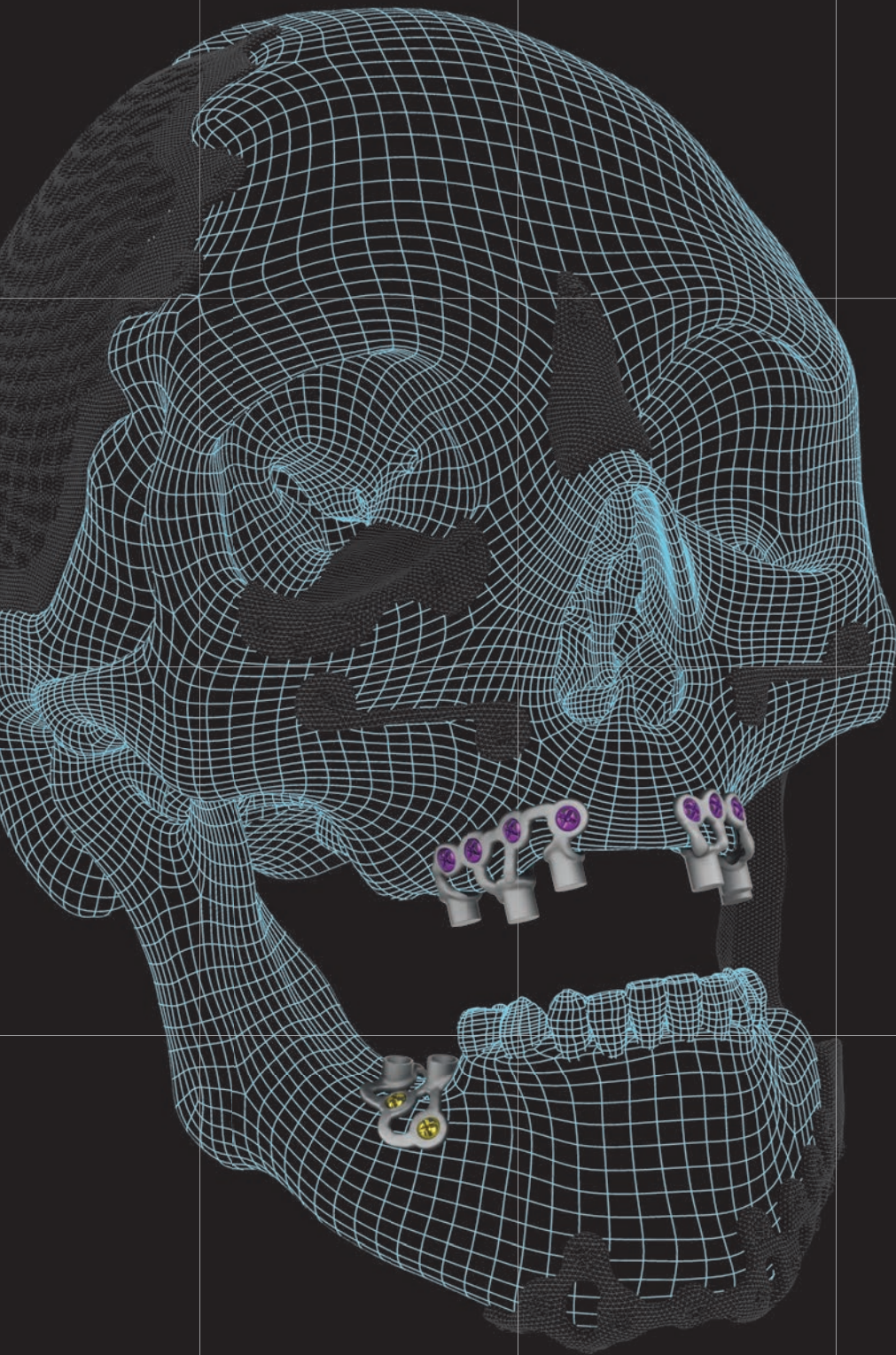
D2-P14a



DBM-DEMINEALIZED BONE MATRIX READY TO USE NO REHYDRATION OR MIXING

Bone Graft - putty texture. Consists of 93% demineralized bone and 7% Hyaluronic acid. Available in a variety of volumes.

AB 3010	DBM PUTTY	0.212-0.85 mm	1cc
AB 3025	DBM PUTTY	0.212-0.85 mm	2.5cc



LASER PRECISION IMPLANT

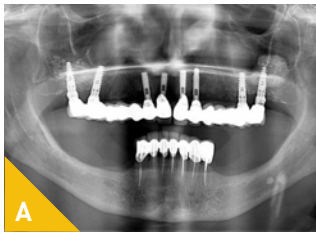**LPI - A subperiosteal implant
for resorbed jaws.**

LASER PRECISION IMPLANT

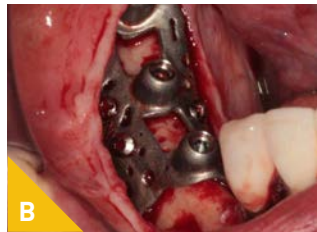#1

Dr. Adrian Kahn

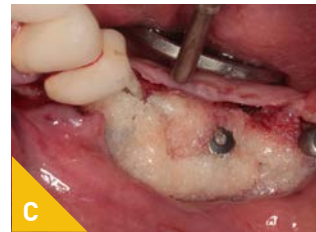Age: 61 | Gender: female | Bilateral mandibular edentulism | Desire for fixed restoration



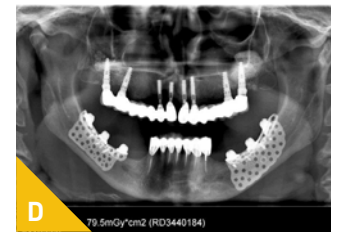A Panoramic view - severe posterior alveolar ridges atrophy



B Right mandibular customized implant - screw fixation



C Demineralized freeze dried bone allograft covering the implant

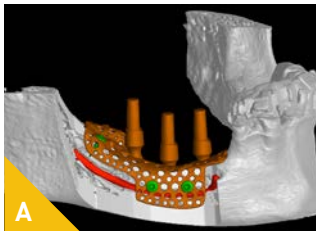


D Postoperative panoramic view

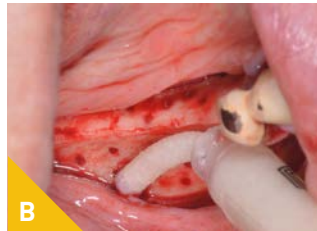#2

Prof. Zvi Schwartz

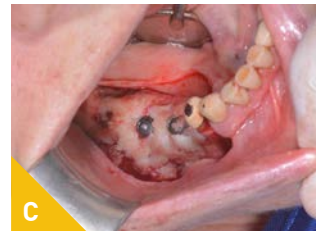Customized subperiosteal implant was created on the right mandible



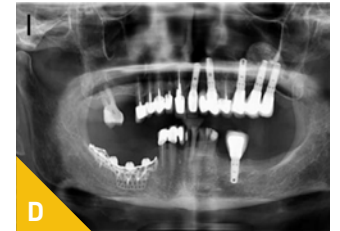A A customized Ti6Al4V implant was designed using software with orange representing implant posts and green representing stabilizing screws



B Bone allograft covering the bone surface



C Implant in position, covered by bone allograft

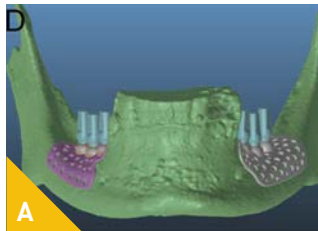


D A follow-up panoramic X-ray was taken to evaluate osteointegration and bone-to-implant contact after three months

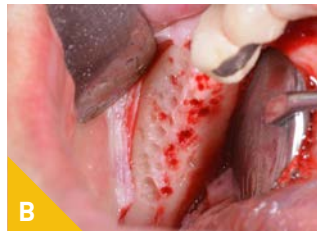#3

Prof. Zvi Schwartz

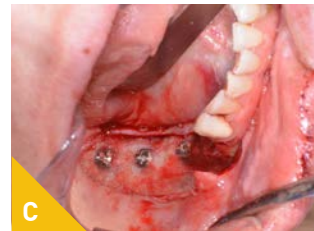Customized subperiosteal implant was created for a situation where there is not enough bone for a conventional implant



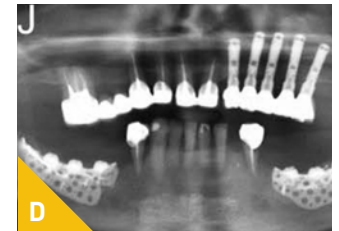
Customized implants were designed using 3D planning



Small holes were drilled into the patient's jaw prior to implant placement to ensure exposure to stem cells and progenitor cells



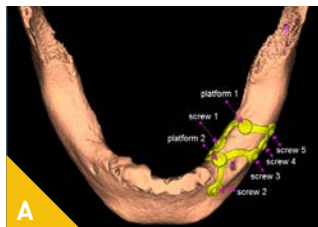Bone allograft placed over the implant



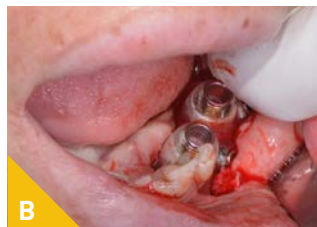A follow-up panoramic X-ray was taken to evaluate osteointegration and bone to-implant contact after three months

#4 Patient specific implant

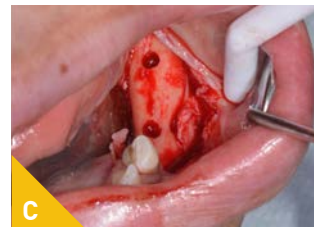LPI - Laser Precision Implant: A subperiosteal implant for resorbed jaws. Customized subperiosteal implant was created for a situation where there is not enough bone for a conventional implant



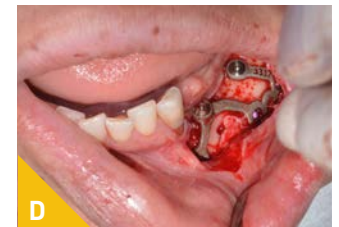3D Computerized Planning, severe posterior alveolar ridges atrophy



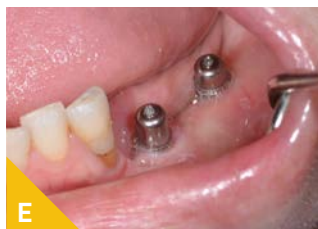A guide to drill the endosseous depth



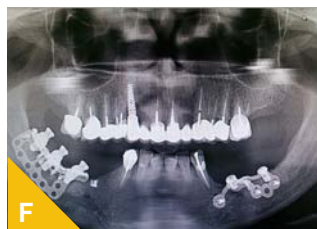After drilling with the guide



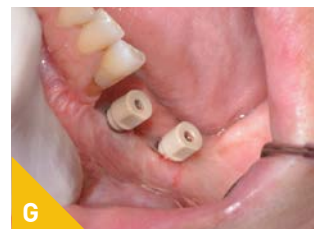U implant fitting accurately into the bone and on the bone surface



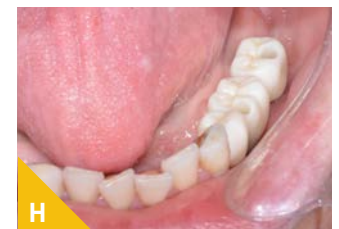Healing caps 6 weeks post-op



Post-op pano xray



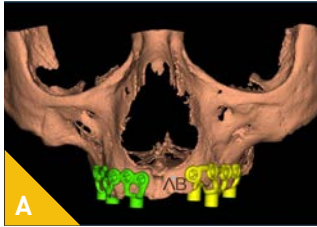
AB scanning abutments for intra-oral scanning



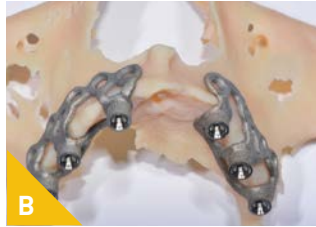Final restoration

#5 TMJ Condyle Replacement

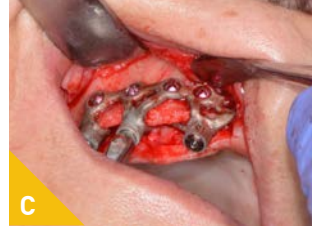LPI - Laser Precision Implant: A subperiosteal implant for resorbed jaws. Customized subperiosteal implant was created for a situation where there is not enough bone for a conventional implant



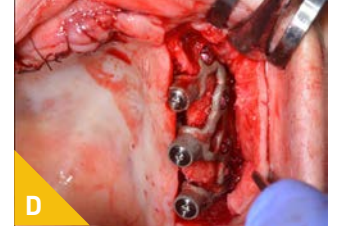A 3D planning on CT of left and right maxilla



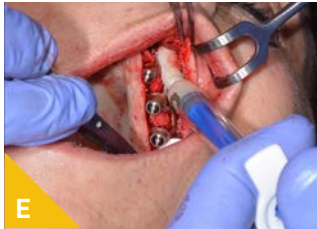B Custom implants left and right on 3D printed model of maxilla



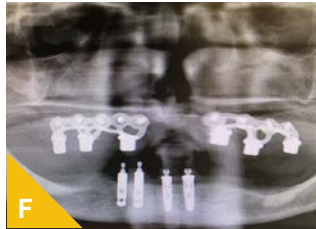
C Right implant fitting accurately with screw fixation



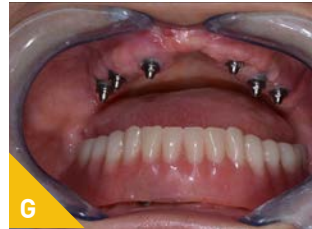D Left implant with cover screws on the abutments



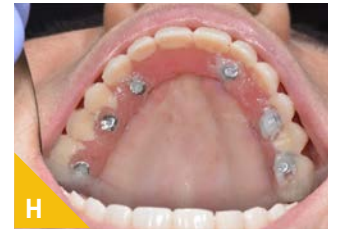E Bone to cover the implant surface for additional augmentation



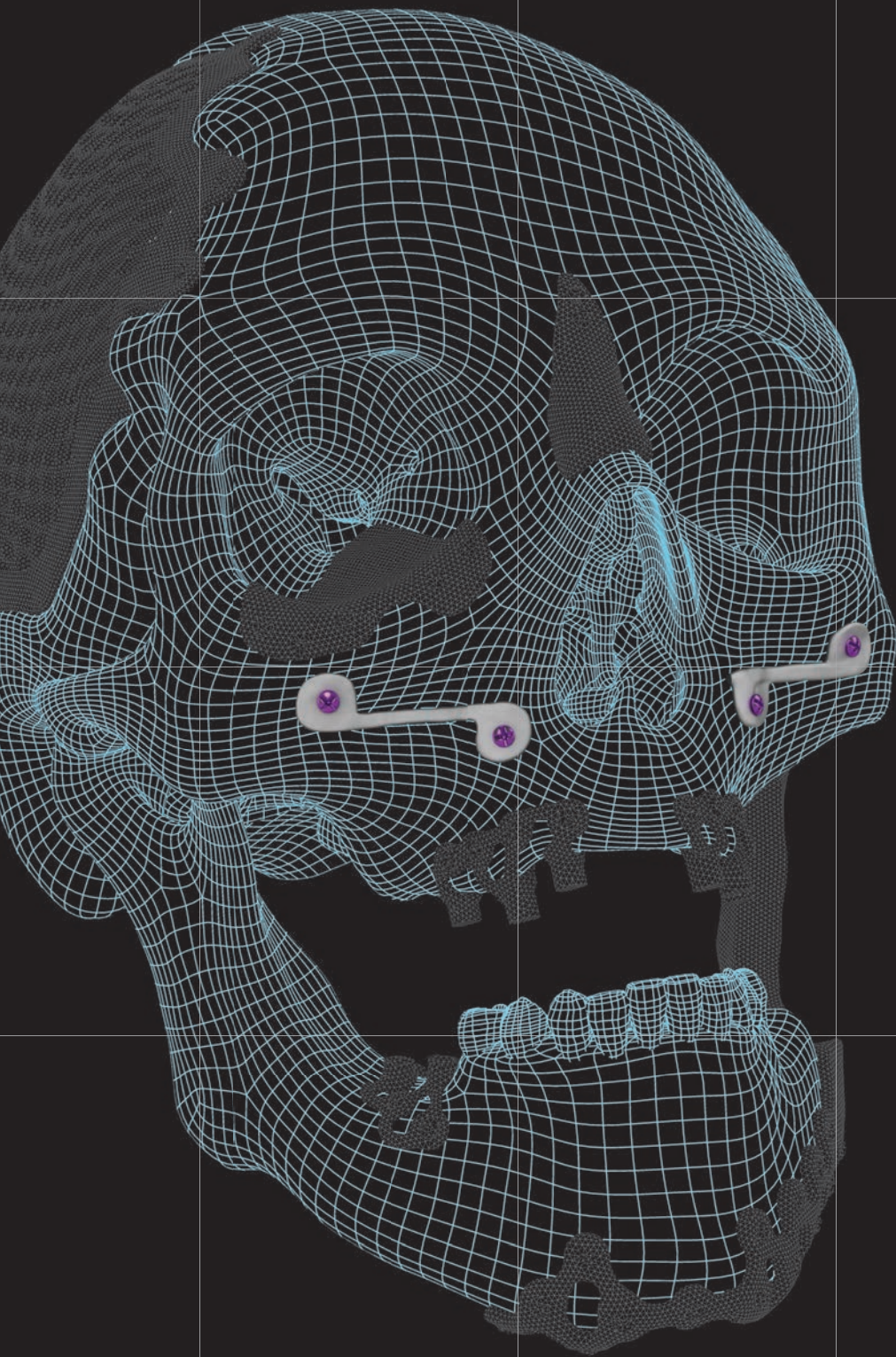
F Post-op pano xray



G 3 months later, with multiunit abutments



H Patient's denture adapted to be temporary screw retained restoration



SINUS ROOF

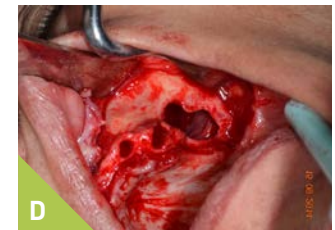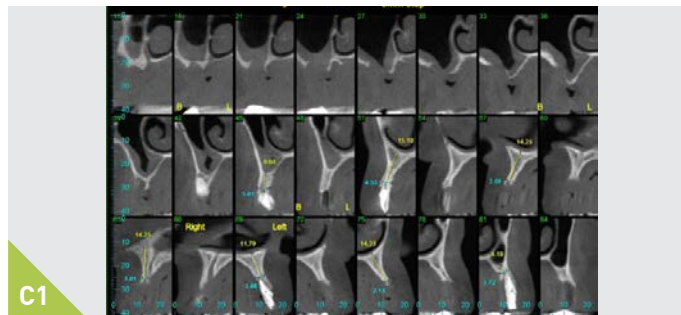
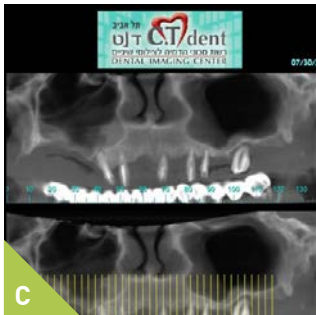
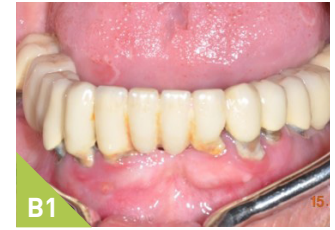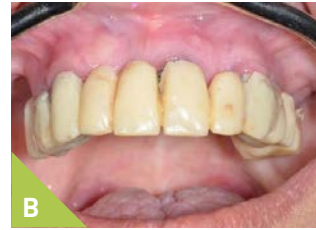**Sinus lift bone
augmentation**

SINUS ROOF

A New 3D "Custom Made Roofing" Technique for Maxillary Sinus Lift Augmentation

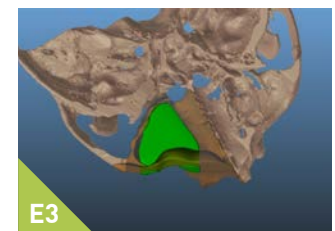
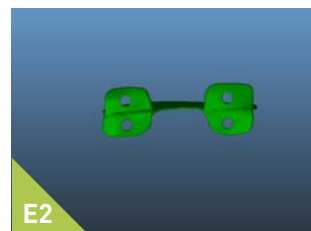
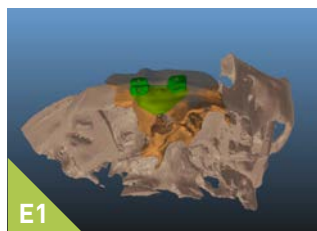
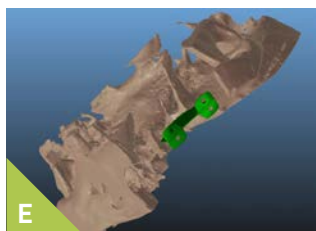
Dr. M. Shteif / Department of Oral, Maxillofacial Surgery, "Carmel" medical center, Haifa, Israel

A 45-year-old woman was referred after failure of sinus augmentation with oro-antral communication for reconstruction of her posterior maxilla.



Pre-op CT

Pre-op clinical view



Virtual planning



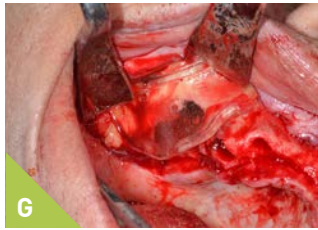Virtual planning

SINUS ROOF - CONTINUED

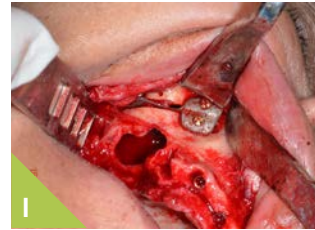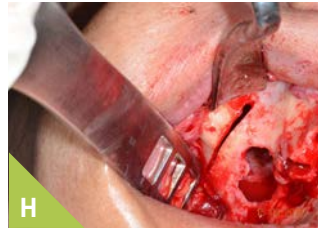A New 3D "Custom Made Roofing" Technique for Maxillary Sinus Lift Augmentation

Dr. M. Shteif / Department of Oral, Maxillofacial Surgery, "Carmel" medical center, Haifa, Israel

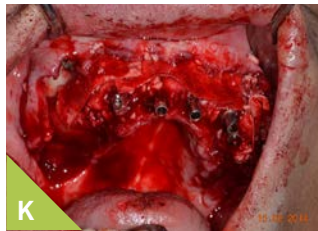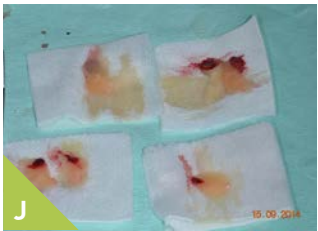
A 45-year-old woman was referred after failure of sinus augmentation with oro-antral communication for reconstruction of her posterior maxilla.



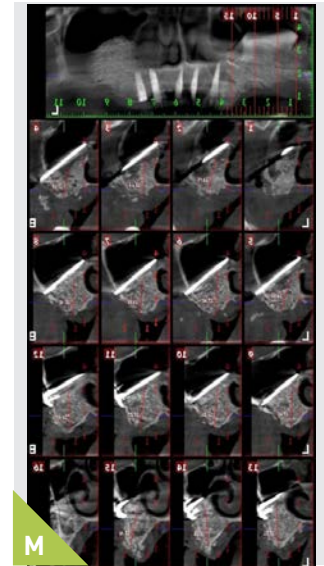
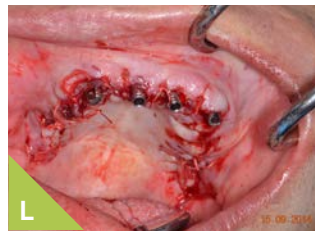
Surgical guide for bonny slot



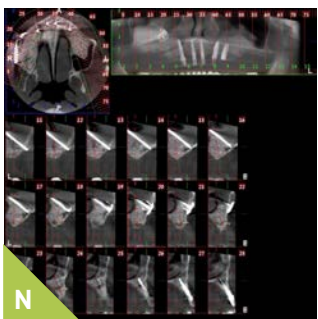
TSR (titanium sinus roofing) insertion



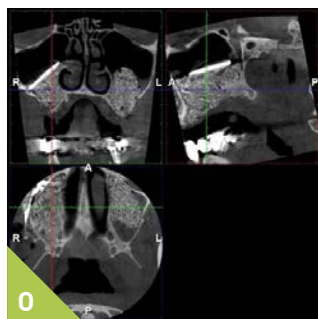
Bone substitute and implants insertion



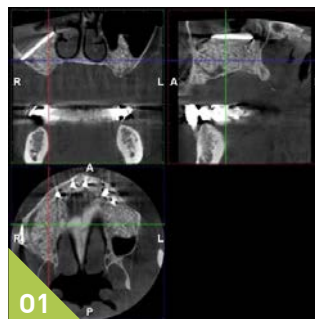
Immediate post op CT



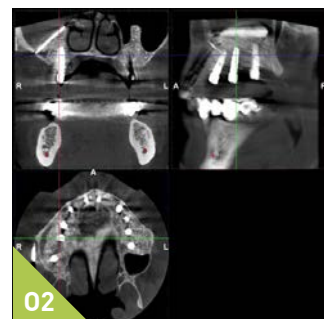7 months' post op CT



Immediate post op CT (with implants)



7 months' post op CT (with implants)



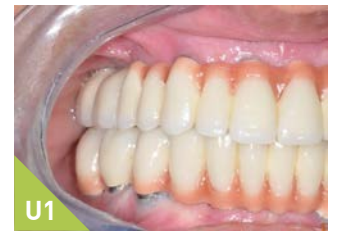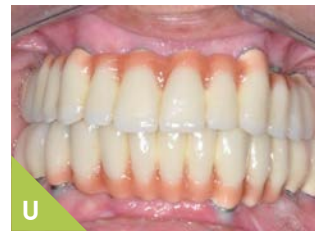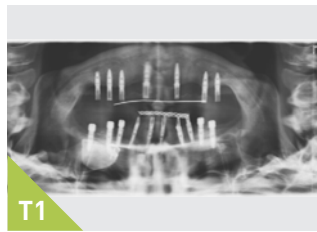
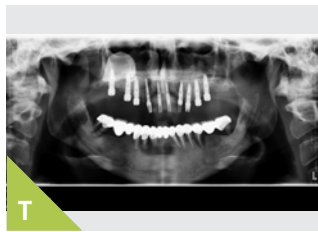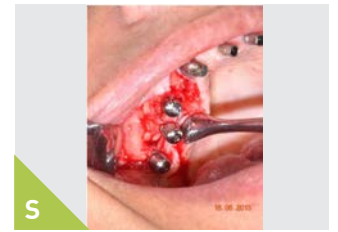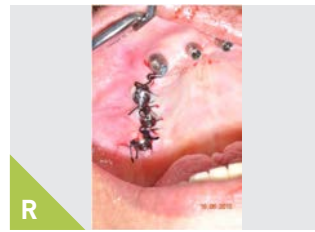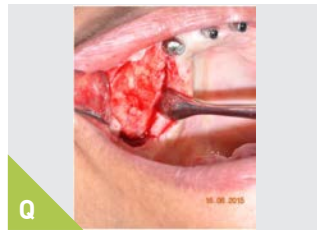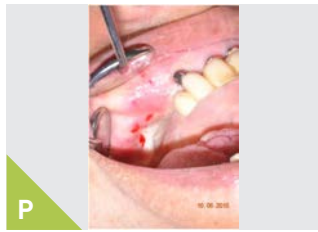10 months' post op CT (with implants)

SINUS ROOF - CONTINUED

A New 3D "Custom Made Roofing" Technique for Maxillary Sinus Lift Augmentation

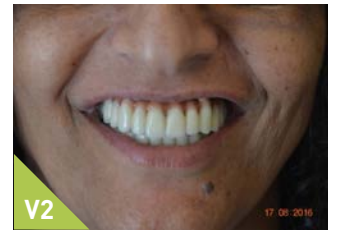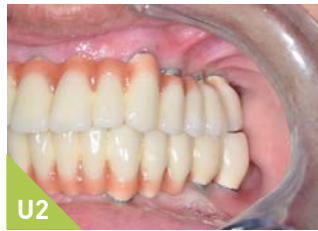Dr. M. Shteif / Department of Oral, Maxillofacial Surgery, "Carmel" medical center, Haifa, Israel

A 45-year-old woman was referred after failure of sinus augmentation with oro-antral communication for reconstruction of her posterior maxilla.

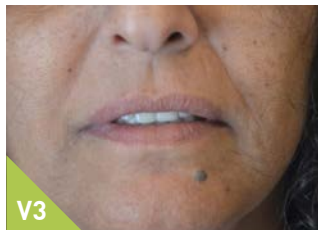

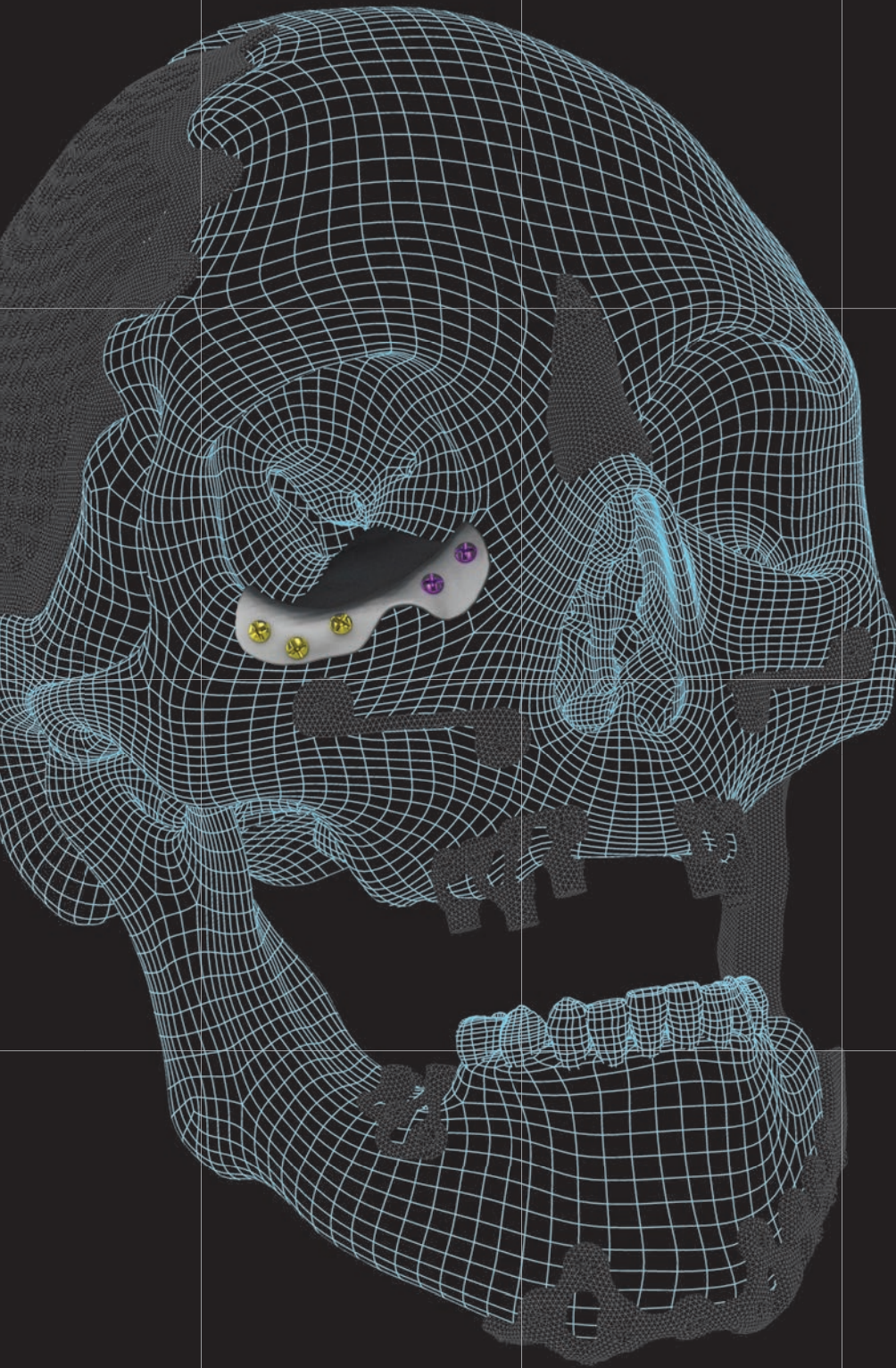
Panoramic view of the Implants

Final restoration



Final restoration





ORBIT

3D Reconstruction
of the orbit

ORBIT

Orbital Floor Reconstruction

Prof. Imad Abu el-Naaj D.M.D / Head, Department of Oral & Maxillofacial Surgery, The Baruch Padeh medical center

Dr. Avi Toeg / Oral & Maxillofacial senior staff specialist, The Baruch Padeh medical center

A 24-year-old patient suffered from a blowout fracture of his left orbital floor, following facial trauma.

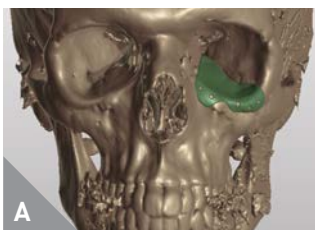
He required reconstruction of the floor. To prevent increased or reduced volume of the orbit, which would result in enophthalmus or exophthalmos.

The conventional treatment to restore the orbital floor using autogenic bone, titanium or vicryl mesh, or other materials. There is difficulty in exactly restoring the shape of the orbit due to the complex anatomy and the danger of damage to the optic nerve.

The implant was designed using the shape of the orbit of the other eye which was intact.

The surgery was made with general anesthetic, and was completed in 20 minutes, using the custom-made implant with screw fixation. Conventional surgery would last more than an hour.

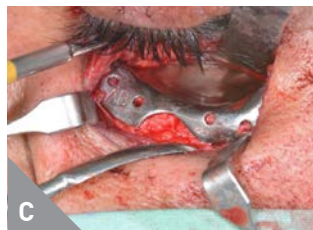The low dose post-op CT shows excellent adaptation, and the patient has full function and aesthetics two years later.



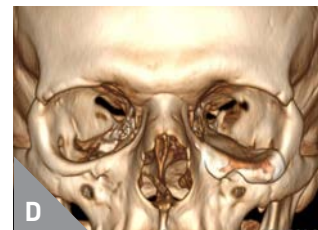Pre-Op 3D Planning



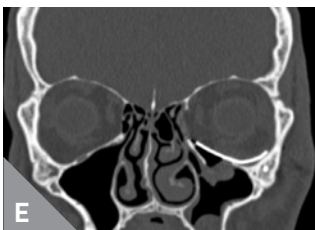Individual Custom
Reconstruction Implant on 3D
Model



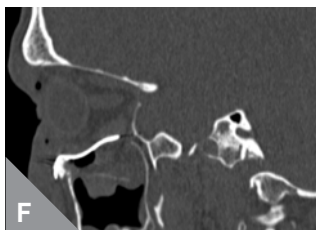
Implant positioned during
surgery



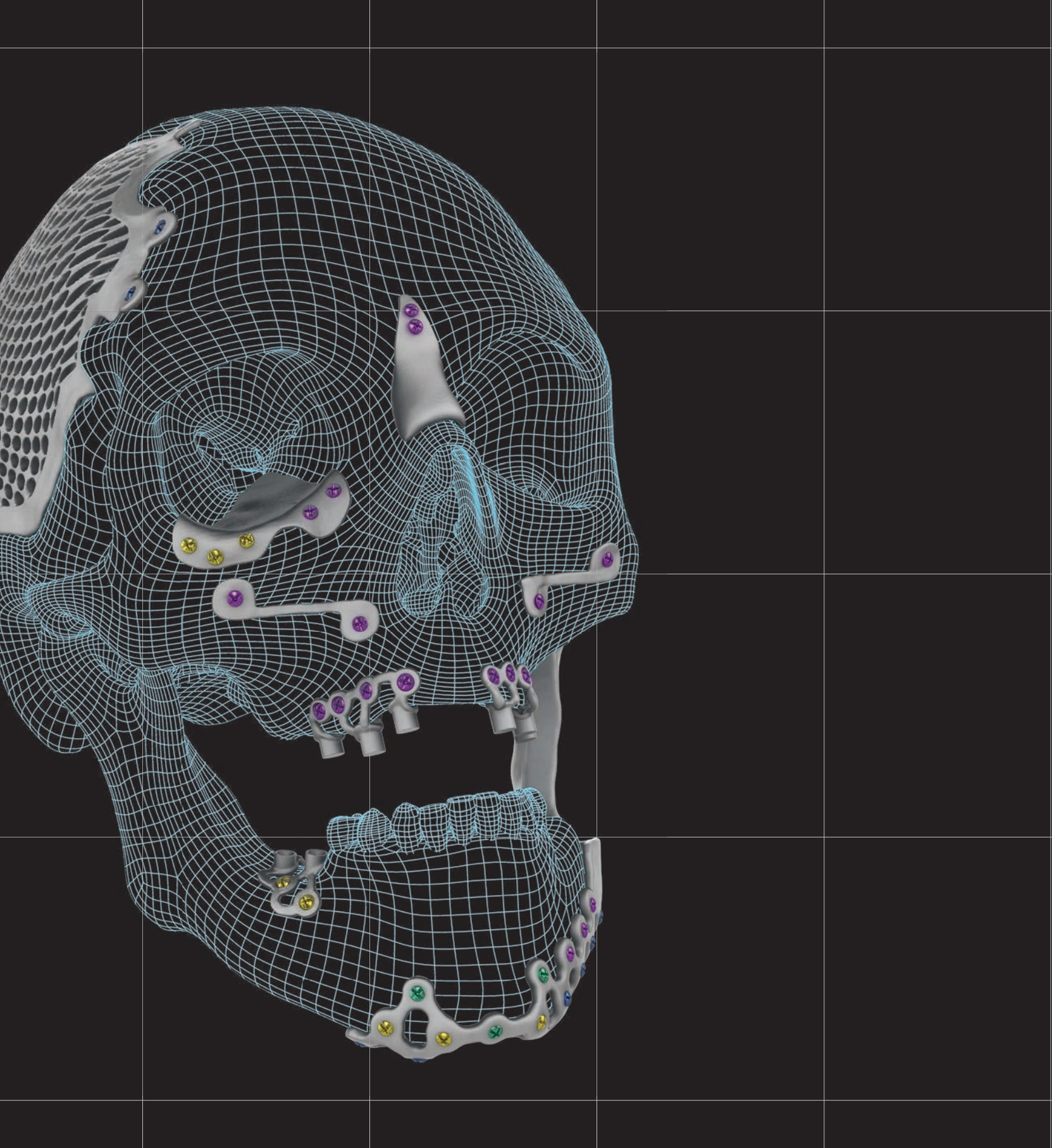
3D Image from Post-Op CT



Post-Op CT: Anterior View



Post-Op CT: Lateral View



CUSTOMIZED FACIAL IMPLANT

Oral and maxillofacial
restoration treatments

CUSTOMIZED FACIAL IMPLANT

#1 TMJ Condyle Replacement

Prof. Imad Abu el-Naaj D.M.D / Head, Department of Oral & Maxillofacial Surgery, The Baruch Padeh medical center

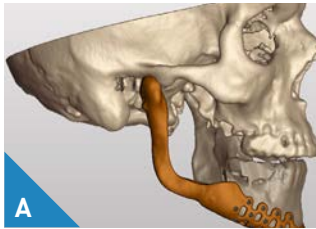
Dr. Avi Toeg / Oral & Maxillofacial senior staff specialist, The Baruch Padeh medical center

A 64-year-old patient with metastatic tumor to his right mandibular ramus. Resection of the tumor required removal of the condyle, resulting in loss of the Temporomandibular Joint. The joint disc was intact.

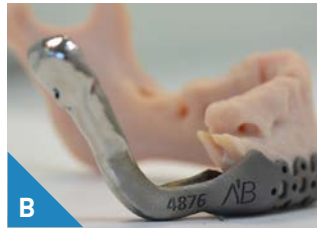The tumor was resected with the help of a 3D Template surgical guide, which enabled cutting the mandible at exactly the planned position. The custom implant was placed using specific screws. The surgery was completed in 2 hours, which was far less than anticipated and less than the conventional treatment with much better recovery. Post op CT showed good position of the condyle in the eminence fossa.

The patient was able to chew 2 days after the surgery, good mouth opening, excellent function with no pain on chewing.

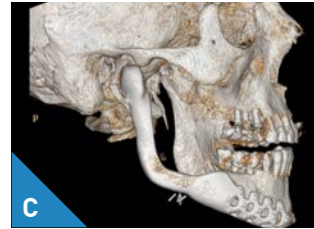After more than one year follow up the patient is functioning with the TMJ prosthesis with no complications.



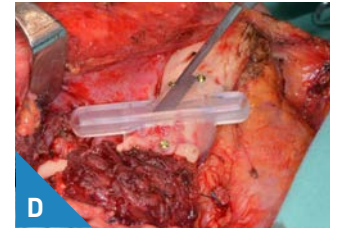
3D Planning



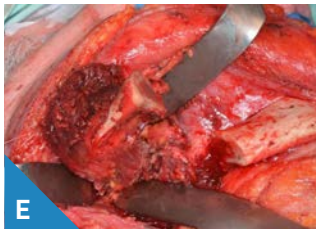
3D Printed stereolitic model & Implant after Virtual Removal of Tumor



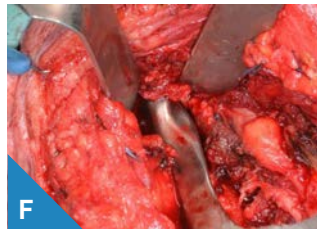
3D Image Post-Op



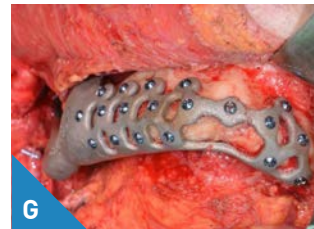The Surgical Procedure: Surgical guide for jaw resection



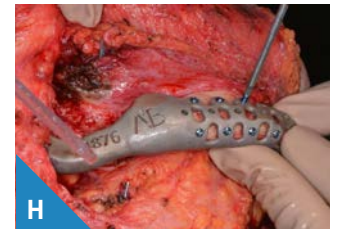Condyle Removal



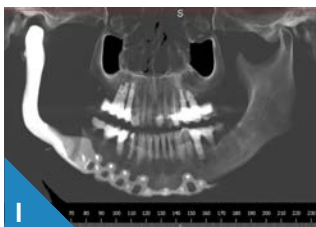
Location of Implant in TMJ



Anterior View of Implant with Fixation Screws



Lateral View of Implant



Panoramic view of Post-Op CT

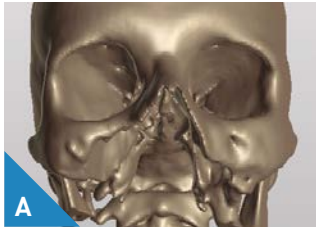#2 Upper Jaw Reconstruction

Dr. Vadim Reiser\ Director of Oral and Maxillofacial Surgery Department of the Tel Aviv Sourasky Medical Center, Dr. Aharon Amir, Assuta Hospital

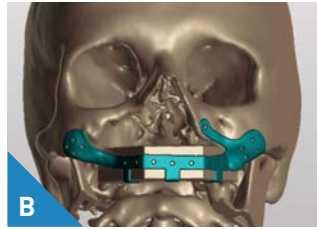Patient Specific Implant to reconstruct maxilla, due to Central Giant Cell Granuloma on the right side.

This 24-year-old patient was diagnosed at an early age with an aggressive benign Central Giant Cell Granuloma on the right side. The right maxilla was removed, extending to 26 area on the left.

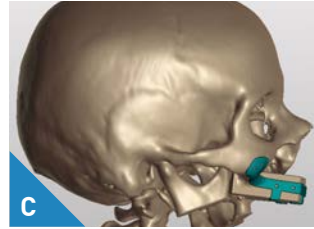The patient had poor aesthetics and function, and speech difficulty.



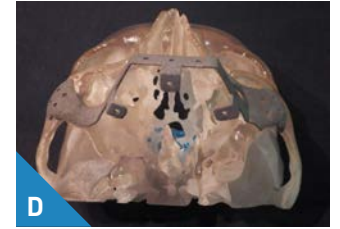
3D Planning of Reconstruction Implant and Bone Shape from Fibula



Reconstructed maxilla based on a 3D image before surgery



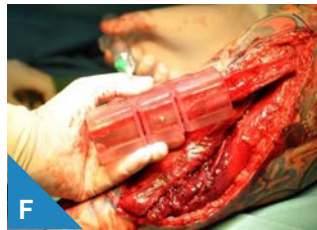The image was superimposed on the new CT.



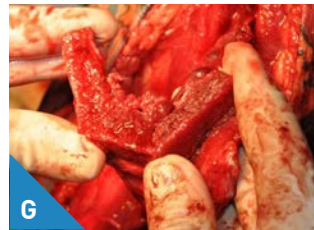Custom Implant on 3D Model



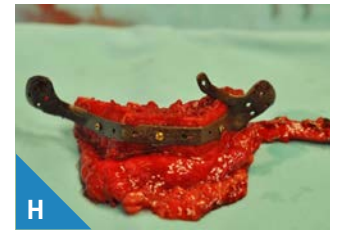Cutting Guide for Leg Fibula Donor Site



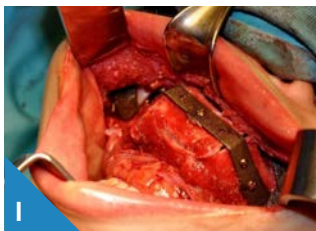
Surgical Process 3D Designed Bone Cutting Guide to remove a precise shape of bone



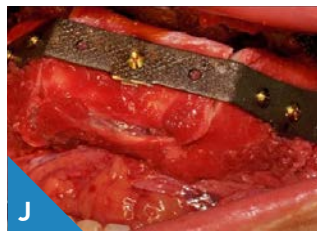Bone from Fibula



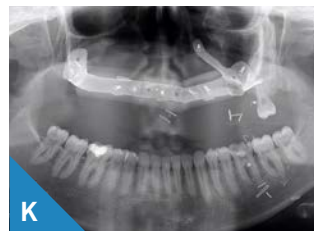Bone with Blood Supply and Reconstruction Implant



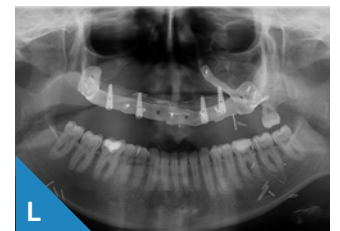Implant and Bone



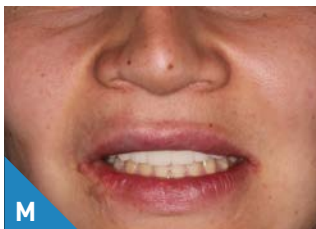Implant and Bone



Post-Op Panoramic Xray



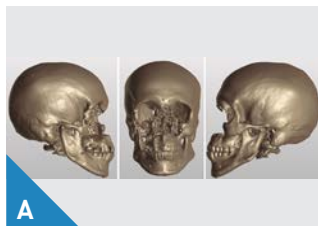6 months' after reconstruction: Panoramic View after Implant Placement



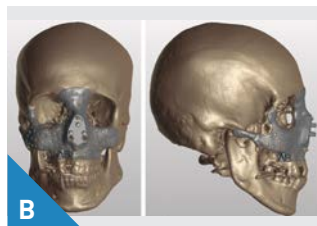Final result

#3 Facial Reconstruction

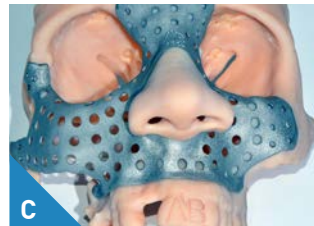
Prof. Samer Srouji DMD, Ph.D / Chief of Oral And Maxillofacial, Oral Medicine Institute, Head Of "Bone Regeneration" Lab, Galilee Medical Center, Naharia



3D Planning of Reconstruction Implant and Bone Shape from Fibula



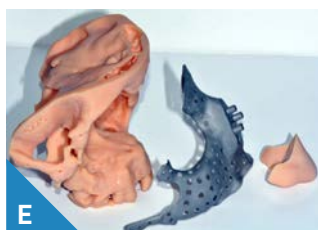The shape of the reconstructed maxilla was based on a 3D image of the patient before her first surgery.



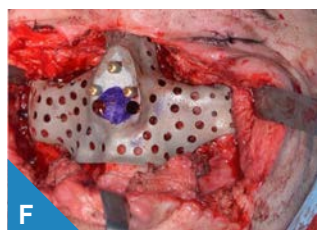
The image was superimposed on the new CT.



Custom Implant on 3D Model



Cutting Guide for Leg Fibula Donor Site



Surgical Process 3D Designed Bone Cutting Guide to remove a precise shape of bone



Functional Reconstruction in Mandibular Avulsion Injuries

Yoav Leiser, DMD, PhD, Dekel Shilo, DMD, PhD, Amir Wolff, DMD, and Adi Rachmiel, DMD, PhD

Published: Volume 27, Number 8, November 2016

Abstract

We describe the planning and surgery as well as pitfalls and management of patients exhibiting near total mandibular avulsion injury rehabilitated using three-dimensional (3D) laser printing of a titanium lower jaw. Laser-sintering involves zapping layers of powdered metal to recreate a 3D implantable skeletal defect.

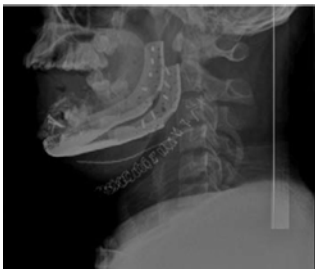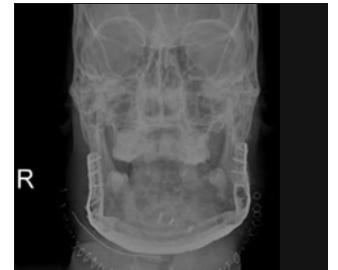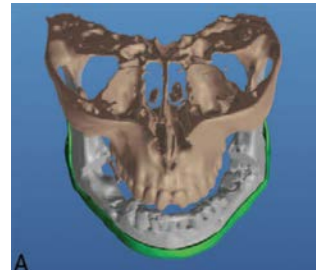
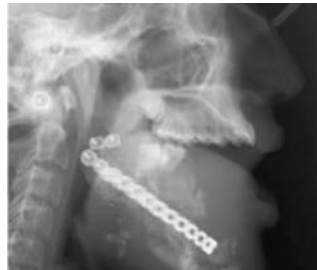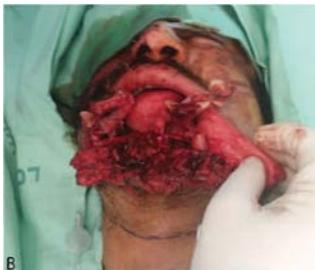The process involves using either mirror imaging of the unaffected side or using archival image database of healthy individuals. A 25-year-old man presented with a gunshot injury that left him with a near total avulsed mandible.

The patient received state-of-the-art treatment using a

laser 3D printed mandible which was connected to the muscles of mastication for functionality.

The inner side of the titanium jaw was filled with the patient's comminuted fractured bones in addition to harvested iliac crest bone graft that was covered with the patient's remaining periosteal tissue.

The implantation of a near total mandible using 3D laser printing is a fast and predictable process that in selected patients can result in aesthetically as well as functionally excellent results. The authors believe that the future of craniofacial reconstruction will employ these methods for facial bony reconstruction.



Reconstruction of complex mandibular defects using integrated dental custom-made titanium implants

A.Rachmiel, D.Shiloa, O.Blanc ,O.Emodi

Published by Elsevier Ltd., 9 January 2017

Abstract

Reconstruction of the craniofacial complex is extremely challenging due to the unique anatomy, presence of vital structures and the diversity of defects. In craniofacial reconstruction, restoration of aesthetics and function is the primary goal.

Auto-grafts are the gold standard for craniofacial skeletal reconstruction, however they possess several disadvantages. These disadvantages led to the research of alloplastic materials.

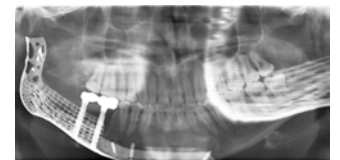
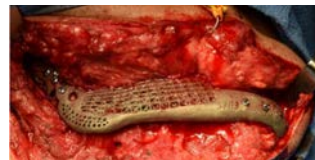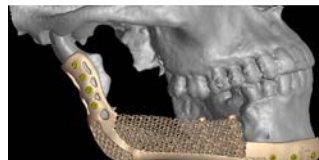
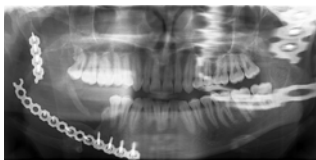Development of computer assisted design and computer assisted manufacturing systems allows for precise preoperative planning and designing of patient specific implants.


Materials and methods: A case of facial bone reconstruction is presented exhibiting major deficiency in the mandible. Reconstruction was performed using a custom-made titanium implant. This implant was shaped as a crib, thus allowing for artificial and autogenous bone

graft augmentation for future implant placement.

Results: The mandibular defect was reconstructed using titanium for strength and function and resulted in proper mouth opening, function and aesthetics. Another innovation was the addition of dental implants which were designed as part of the patient specific implant thus allowing for future implant supported dental rehabilitation not necessarily requiring support of the bone graft.

Conclusions: Individual computer assisted design & computer assisted manufacturing systems for pre-existing facial defects can become an alternative to auto-grafts. Results are promising and exhibit excellent aesthetic and functional outcomes, while reducing operating time and avoiding donor site morbidity. This procedure provides a simple way to reconstruct a complex three-dimensional structure with precision which is difficult achieving with standard methods.





DMS 14502
Rev. 0319
Tel: +972-8-8531388
Fax: +972-8-8522562
www.ab-dent.com



Superior Implant Technology